



High resolution ultrasound scanner for skin imaging

Christine Turlat
Sales Director
Atys medical
17 Parc d'Arbora
69510 SOUCIEU EN JARREST



High resolution ultrasound scanner

Atys company
Principle of ultrasound imaging
DERMCUP
Normal image of skin
Examples of applications
Conclusion



High resolution ultrasound scanner

Atys medical



17 Parc d'Arbora
69510 SOUCIEU EN JARREST
NEAR LYON
FRANCE

Year of creation: 1990

Privately owned company

Activity: design, manufacturing
& sales of medical devices

French leader in its field



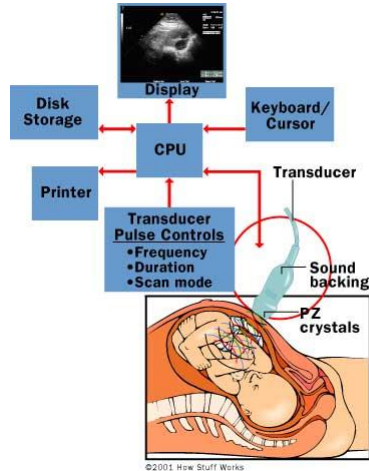
High resolution ultrasound scanner

ATYS medical range of products

			
			
Vascular Doppler	Vascular laboratory	Transcranial Doppler	Ultrasound scanner
Vascular specialist		Neurologist, ICU, intensivist	Dermatologists...

Principle of ultrasound

- Medical ultrasound imaging is ultrasound that is converted to an image
- Diagnostic Medical applications in use since late 1950's
- Frequency ranges used in medical ultrasound imaging are 2 - 15 MHz
General abdomen, OB/Gyn: 3.5MHz
- The use of these frequencies for the diagnosis of process (size of 0.1 mm) limited to the corium is inadequate or impossible. They do not provide satisfactory image of the dermis.
- **DERMCUP: 25 MHz**



Principle of ultrasound

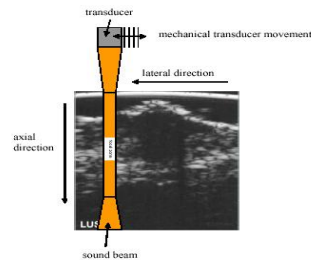
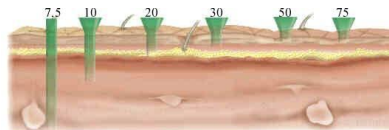
Transducer frequency

Higher frequency = higher axial resolution
Lateral resolution depends on the beam
Higher Frequency = lower penetration

Resolution: ability to distinguish two structures that are close together as separate.

The ideal situation is to use the highest frequency possible to achieve penetration to the area of interest.

Typical diagnostic ultrasound for fetal imaging is around 3.5 to 7 MHz. DERMICUP uses 25 MHz central frequency probes. This makes it suitable for imaging the skin and superficial soft tissue to a depth of approximately 1 cm.



Principle of ultrasound

The probe includes a piezoelectric crystal

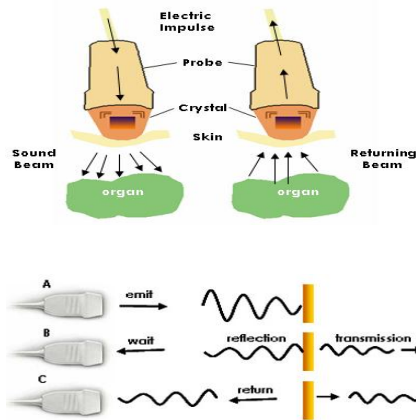
The sound waves are focused into a beam and transmitted in the soft tissues of the body.

The transducer pauses to received the reflected waves

When the sound waves hit a boundary between acoustically different tissues some of the waves are reflected back.

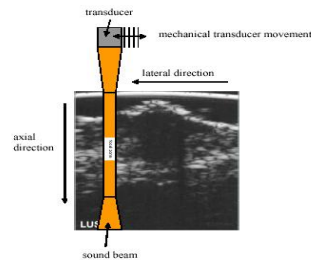
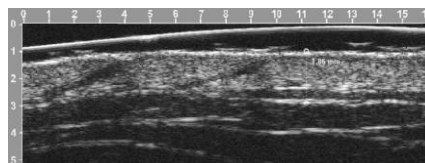
Other waves travel further until they reach another boundary.

The reflected waves interact with the piezoelectric crystal to produce a small current. These signals are processed by the ultrasound machine that calculates the location and intensity of these reflections.



How is the B-mode format image formed on the monitor?

- The imager displays a real time two dimensional image.
- The strength or amplitude (brightness) of each reflected wave is represented by a dot.
- The position of the dot represents the depth from which the returning echo was received
- These dots are combined to form a complete image
- The DERMICUP uses a single element transducer driven by a small motor that transverses back and forth within the probe.





High resolution ultrasound scanner

DERMCUP features

Frequency: 16, 20, 25 MHz

Sectorial probe

- Scanning length: 6 mm
produces sector or pie-shaped image

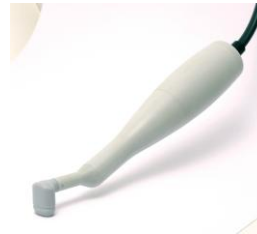Linear probe

- Scanning length: 16 mm

Resolution @ 25 MHz

- axial: 60 μm
- lateral: 150 μm

Exploration depth: 12 mm



High resolution ultrasound scanner

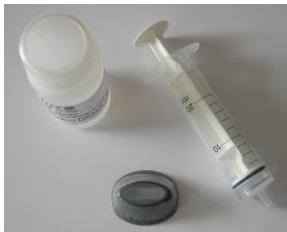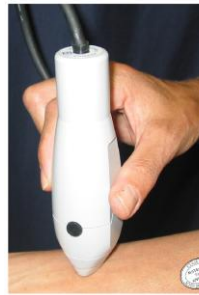DERMCUP probe

Easy to use

- Probe perpendicular to the skin
- Apply minimum pressure
- Apply gel between probe and skin

Easy to maintain

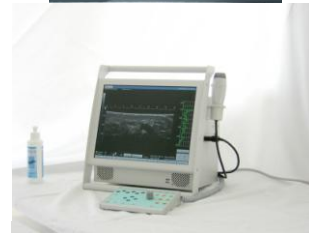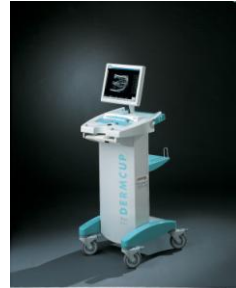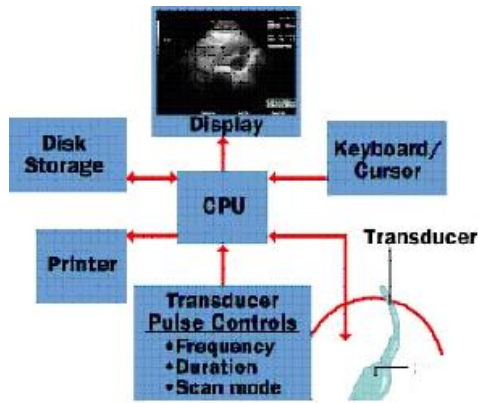
- Water chamber filling
- Membrane replacement





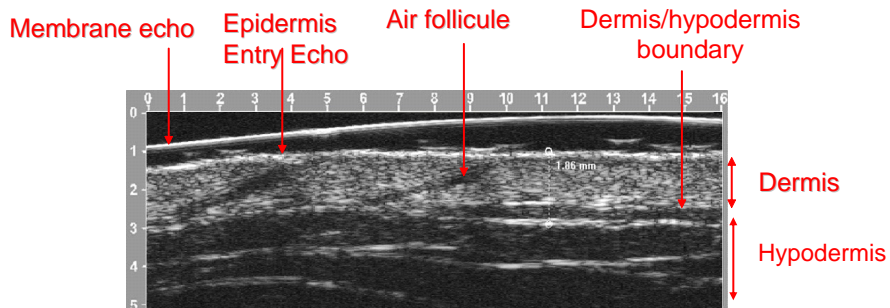
High resolution ultrasound scanner

DERMCUP components



High resolution ultrasound scanner

DERMCUP skin image



Horizontal structure of the skin or fibrillar network comprised of collagen and elastic fibers. This is the fibrillar network that is responsible for ultrasound echogenicity of the dermis.

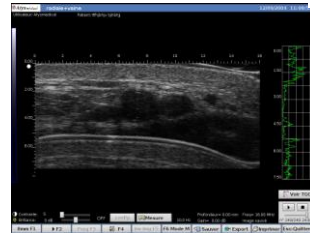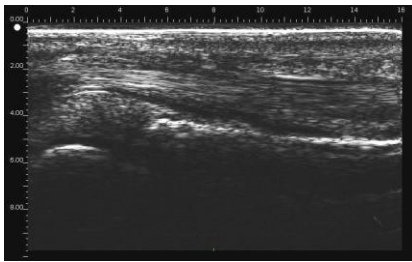
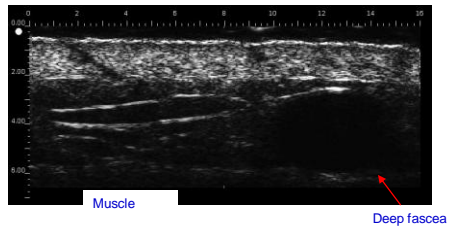The dermis provides a natural contrast medium in which different pathologies can be outlined if they cause low reflectancy or disturbance of interface and dimensions.



High resolution ultrasound scanner

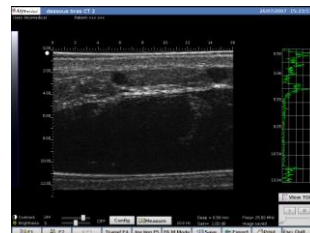
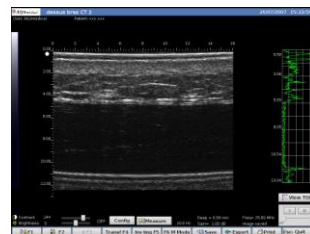
DERMCUP skin image

- Structures such as blood vessels, glands, fascia and adipose tissue can be seen in the hypodermis.
- The deep fascia can be identified below a layer of subcutaneous tissue
- Muscles have few internal echoes.
- Bones cause heavy reflection.



High resolution ultrasound scanner

The thickness of dermis varies with anatomic area.





High resolution ultrasound scanner

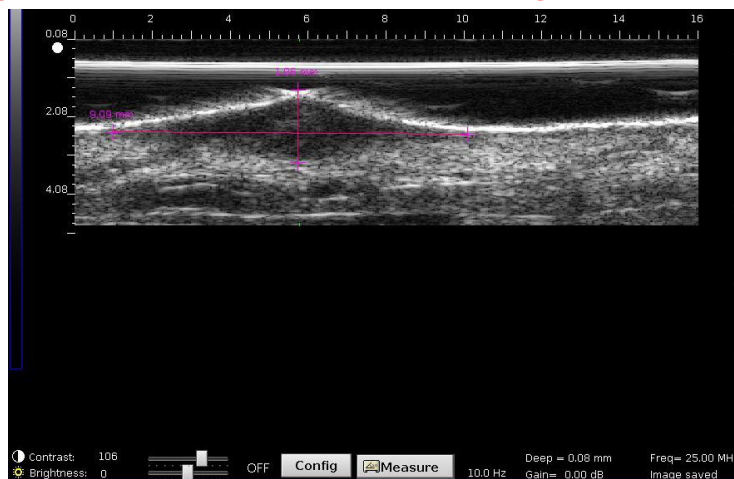DERMCUP applications

- Vertical skin cross section in vivo
- Accurate non invasive measuring device for skin pathology
- Skin cancer management applications
 - Assessment of the size of the tumours to aid in surgical planning
 - Improvement of the accuracy of the clinical diagnosis
 - Assessment of the efficiency of the treatment
- Objective 2 D documentation for most treatment modalities
- Quantitative 2 D evaluation of response to topical treatments

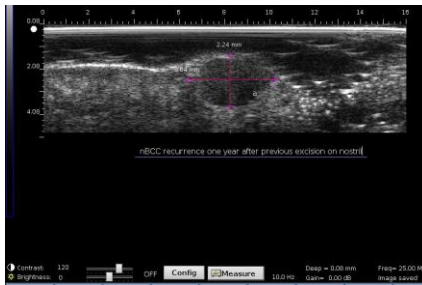


High resolution ultrasound scanner

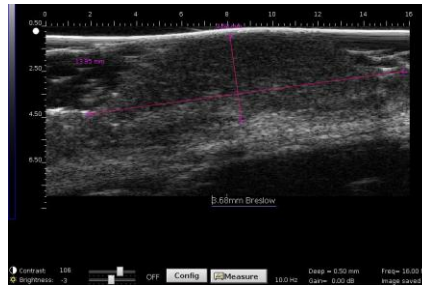
Sagittal scan solid BCC lower leg



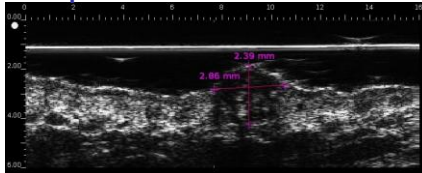
Recurrence nBCC
on left nostril
(1 year after surgery)



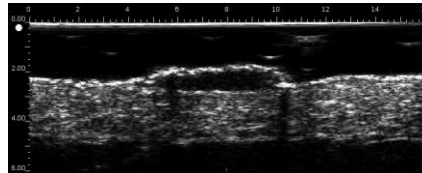
Pre-op Breslow's 3.68mm
(histology 3.7mm Level IV)



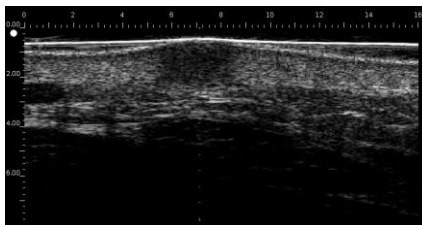
Compound nevus of the dermis



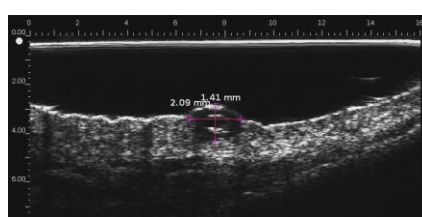
Seborrhoeic keratosis



Histiocytofibroma



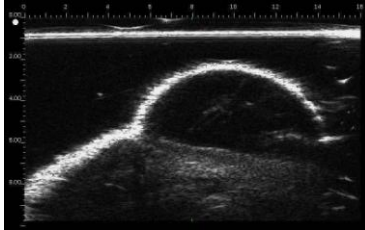
Epidermal cyst



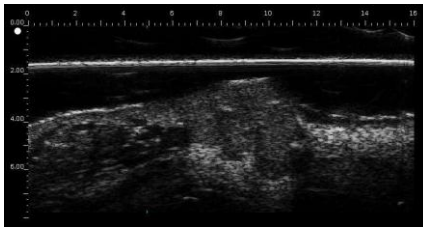
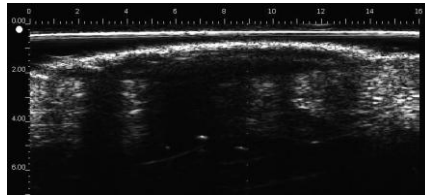


High resolution ultrasound scanner

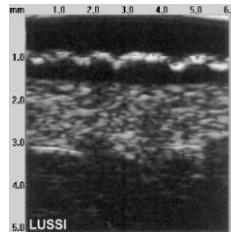
Subepidermal bubble



Seborrhoeic wart



Angioma of the lip

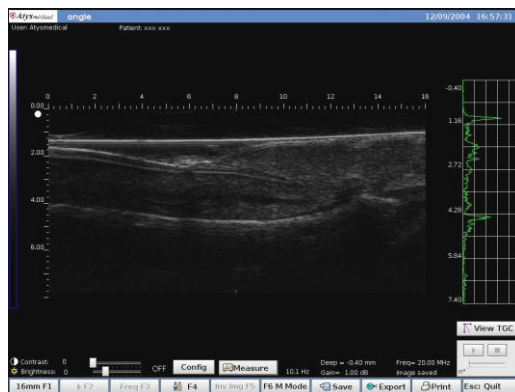

psoriasis



High resolution ultrasound scanner

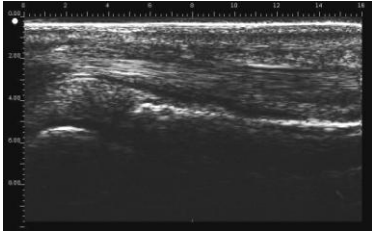
Nail and subungual space



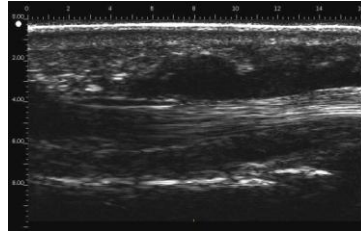
Nail
Root
Subungual

Helpful in diagnosis of glomus tumors which are often located under the nail

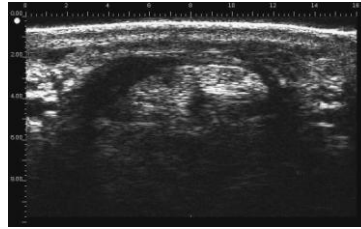
High resolution ultrasound scanner Tendon



Normal finger tendon
(longitudinal)

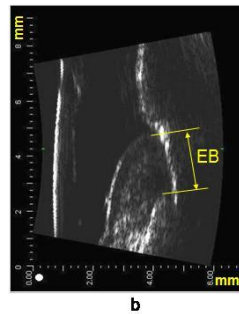
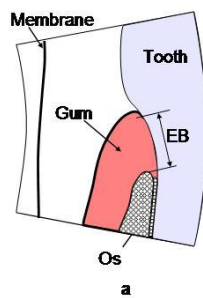


Tendon with inflammation
(longitudinal & transversal)



High resolution ultrasound scanner

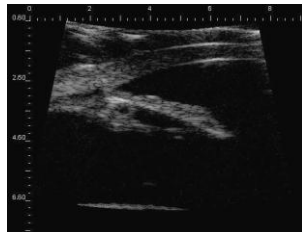
Gum



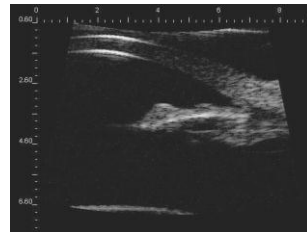

High resolution ultrasound scanner

Eye



Eye

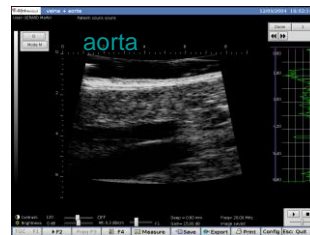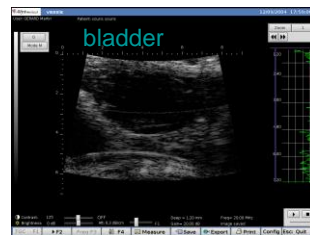

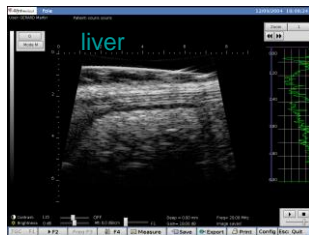
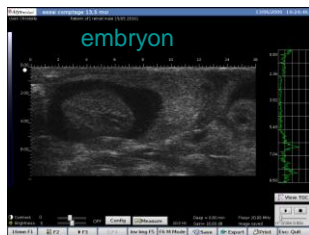Injured eye



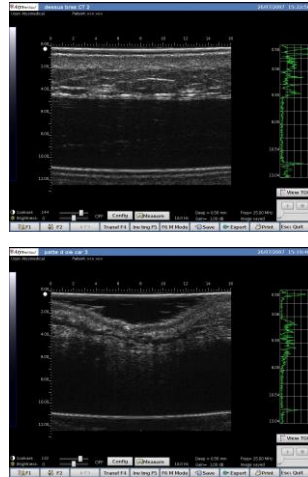
High resolution ultrasound scanner

Small laboratory animals - mice



Dermo cosmetic applications

- Quantitative and objective evaluation of treatments
- Thickness of the dermis
(Ultrasound imaging demonstration of the improvement of non-ablative laser remodeling by concomitant daily topical application of 0.05% retinaldehyde)
- Collagen concentration: brightness
- Ultrasound reveals the appearance of a subepidermal low echogenic band that thickens with age, especially in environmentally exposed areas.



Advantages of ultrasound imaging

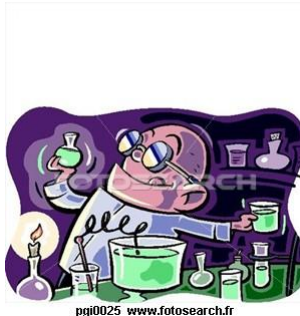- Non invasive
- Safe for the patients and the users
- Can be repeated as often as necessary
- Quite affordable
- Quantitative and objective evaluation
- Not time consuming
- No special preparation of the patient



High resolution ultrasound scanner

FUTURE EVOLUTIONS

- Higher frequency: up to 50 MHz
- Implementation of a Doppler module to study the vascular flow
- 3 D probe



High resolution ultrasound scanner

Thank you for your attention